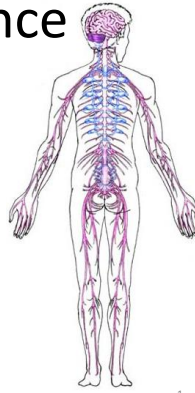


CISC 3250

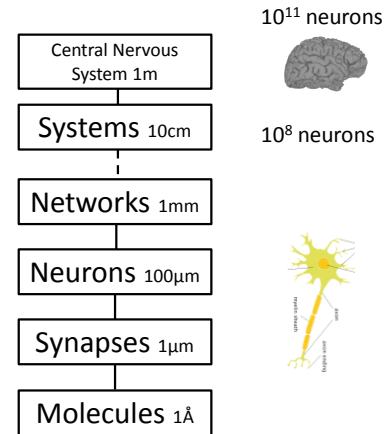
Systems Neuroscience

Neural systems and
neuroanatomy

Professor Daniel Leeds
dleeds@fordham.edu
JMH 332



Levels of organization



Elements of the central nervous system

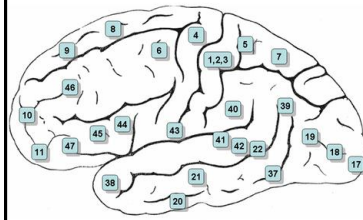
- Cerebral cortex ■
 - Thalamus ■
 - Hypothalamus ■
 - Brainstem ■ ■ ■
 - Cerebellum ■
 - Spinal cord
- Lateral (outside) view
-
- Medial (inside) view
-
- 3

Cerebral cortex broad divisions


- Four lobes
 - Frontal ■
 - Parietal ■
 - Temporal ■
 - Occipital ■
 - Two hemispheres: left and right, linked by corpus callosum
- Lateral view
-
- Dorsal (top) view
-
- left right

Brodmann areas

- Divide brain based on arrangement of neurons in each region



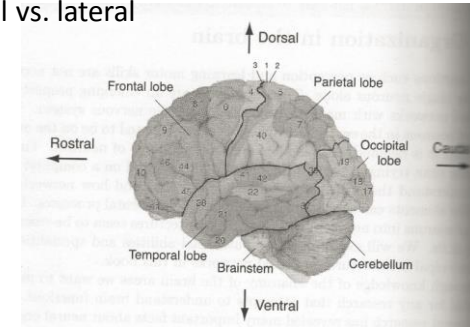
Lateral view



5

Navigating the cerebral cortex

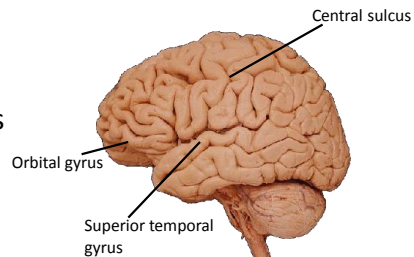
- Dorsal/superior (top) vs. ventral/inferior (bottom)
- Anterior/rostral (front) vs. posterior/caudal (back)
- Medial vs. lateral



6

Dividing the cerebral cortex surface

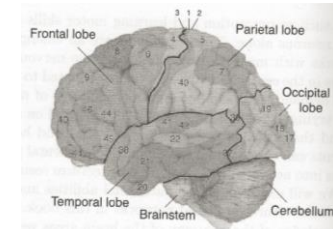
- Sulci – folds
- Gyri – bulges



7

Functional divisions

- Frontal
 - Future planning, personality, judgment, social behavior
 - Motor cortex
- Temporal
 - Auditory cortex
 - High-level vision
- Parietal
 - Spatial vision
 - Primary sensory cortex
 - Visual-auditory-spatial sensory integration
- Occipital
 - Primary visual cortex

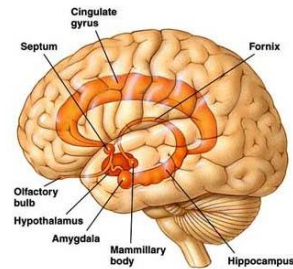


8

Limbic system – memory/emotion

Medial area of cerebral cortex

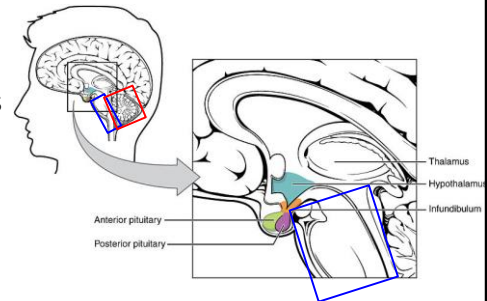
- Hippocampus: memory
- Amygdala: emotion
- Cingulate and parahippocampal gyri



9

The brain beyond the neocortex

- Thalamus
- Hypothalamus
- **Brain Stem**
- **Cerebellum**

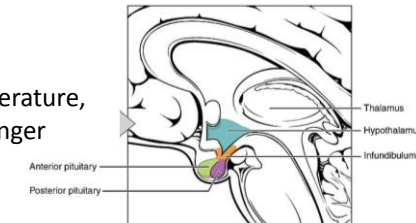


Creative Commons, some right reserved
http://en.wikipedia.org/wiki/File:1806_The_Hypothalamus-Pituitary_Complex.jpg

10

The brain beyond the neocortex

- Thalamus
 - All sensory information (except olfaction/smell) passes through
- Hypothalamus
 - Emotions, memory
 - Homeostasis: temperature, sleep/alertness, hunger

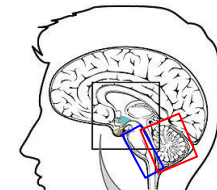


Creative Commons, some right reserved
http://en.wikipedia.org/wiki/File:1806_The_Hypothalamus-Pituitary_Complex.jpg

11

The brain beyond the neocortex

- Brain Stem
 - Conduit for spinal cord and cranial nerves
 - Respiratory and cardiac activity
- Cerebellum
 - Plan, coordinate, modify motor activities

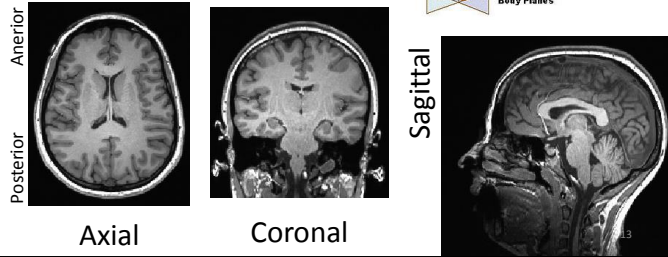
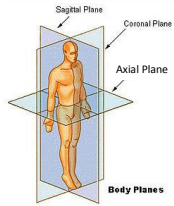


Creative Commons, some right reserved
http://en.wikipedia.org/wiki/File:1806_The_Hypothalamus-Pituitary_Complex.jpg

12

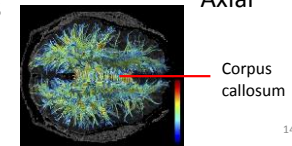
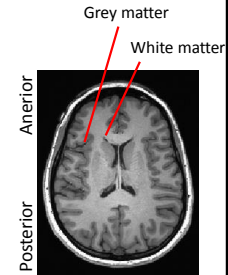
Two dimensional slices of the brain

- Axial (parallel with ground)
- Coronal (halo)
- Sagittal (in profile)



Grey and white matter

- Grey matter – soma, performs “computations”
- White matter (60% of brain) – axons, transmits information
- Tractography finds links between brain regions

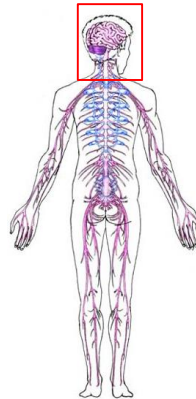


Creative Commons, some right reserved
<http://en.wikipedia.org/wiki/File:3DSlicer-KubickiPR2007-fig6.jpg>

14

At the periphery

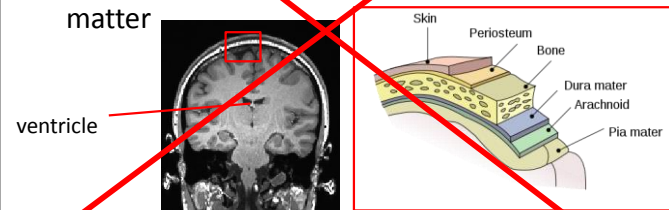
- Spinal cord
 - Muscles: motor
 - Mechanoreceptors: touch
- Sensory organs
 - Ears: Hearing and balance
 - Eyes: Vision
 - Olfactory bulb: smell



15

Non-functional anatomy

- Vessels of the brain
- Ventricles with cerebrospinal fluid
- Casing around the brain – pia mater, dura matter



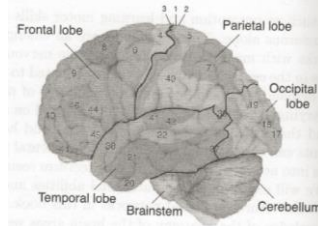
ventricle

Coronal

16

Cortical division review

- Frontal
 - Future planning, personality, judgment, social behavior
 - Motor cortex
- Temporal
 - Auditory cortex
 - High-level vision
- Parietal
 - Spatial vision
 - Primary sensory cortex
 - Visual-auditory-spatial sensory integration
- Occipital
 - Primary visual cortex

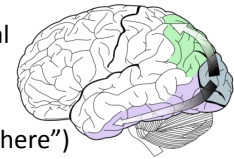


17

Cortical processing networks

Perception “hierarchy”

- *Primary sensory areas* capture basic sensory properties, or “features”
- More complex representations in higher sensory areas
- Example: Vision
 - Primary visual cortex in occipital pole
 - Anterior flow of information in ventral (“what”) and dorsal (“where”) pathways



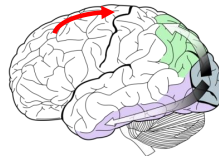
Creative Commons, some rights reserved
http://en.wikipedia.org/wiki/File:Ventral-dorsal_streams.svg

18

Cortical processing networks

Action

- Motor planning and performance is achieved in stages within the frontal lobe
- Motor correction is supervised by the cerebellum

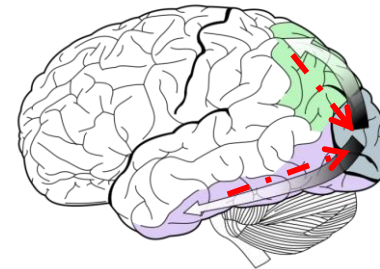


Creative Commons, some rights reserved
http://en.wikipedia.org/wiki/File:Ventral-dorsal_streams.svg

19

Complexity of cortical networks

- *Feedback*: connections in both directions along cortical “pathways”

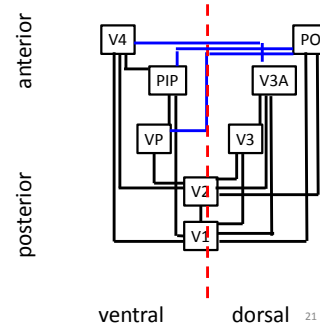


Creative Commons, some rights reserved
http://en.wikipedia.org/wiki/File:Ventral-dorsal_streams.svg

20

Complexity of cortical networks

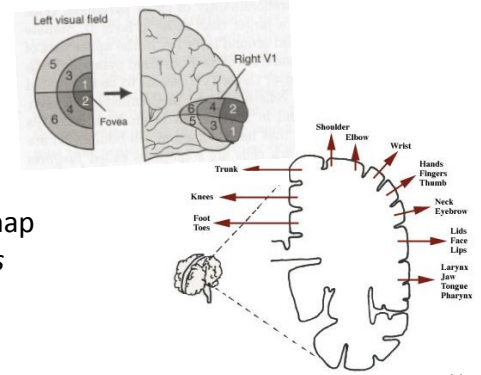
- *Lateral connections:* collaboration among cortical regions at similar stage of processing
- *Multi-level connections:* shortcuts between "early" and "late" processing stages



21

Cortical modules

Groups/"columns" of neurons encoding same property
Subdivisions within cortical region



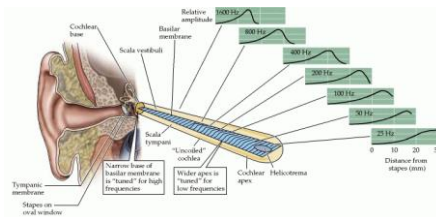
Walter Crane, <http://www.csuchico.edu/~amcaffrey/yltabi/CM5D%2020/362unit4.html>

- Retinotopy
- Body part map *Homunculus*

Cortical modules

Groups/"columns" of neurons encoding same property
Subdivisions within cortical region

- Retinotopy
- Body part map *Homunculus*
- Tonotopy



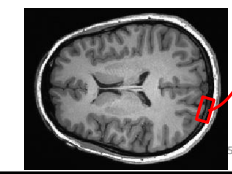
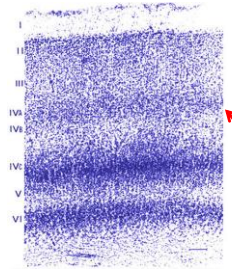
<http://www.ncbi.nlm.nih.gov/books/NBK10946/>

24

Local cortical structure

Six cortical layers

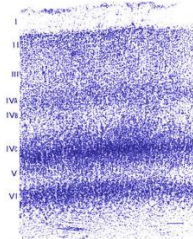
- Layers contain different neuron types
- Nissl staining shows concentration of somas (here, primary visual cortex)



Local cortical structure

Six cortical layers

- Layer IV for input
- Layer V for output
- Layers II & III for lateral connections
- Layer I – largely axons/dendrites

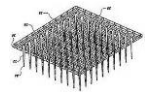


26

Recording activity in the brain

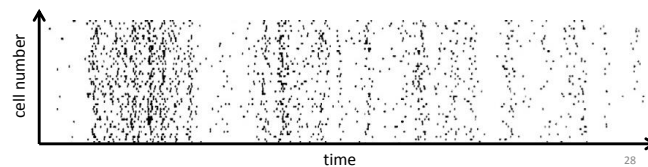
- Electrode recordings
 - Invasive
 - Single neurons close together
- Neuroimaging
 - Non-invasive
 - Hundreds-millions of neurons broadly distributed
- Behavior
 - Non-invasive
 - Overall cognition

27



Electrode recordings

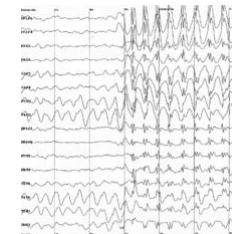
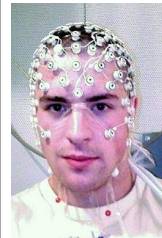- Membrane potentials
- Spike times
- High temporal resolution (ms)
- High spatial resolution (individual neurons)
- Low field of view (small recording area)



28

Electroencephalography (EEG)

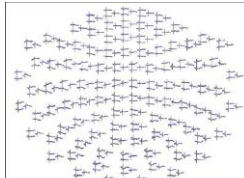
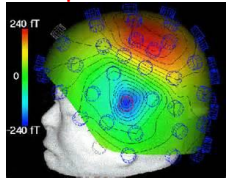
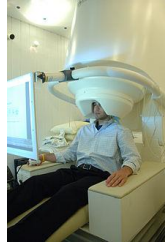- Records electric fields at skull surface
- ~100 sensors across the head
- low spatial resolution
- high (ms) time resolution
- cheap



29

Magnetoencephalography (MEG)

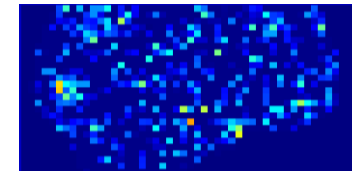
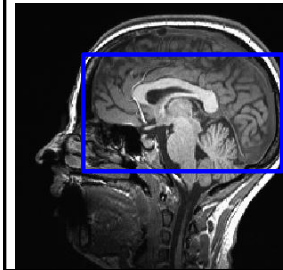
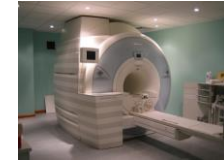- Records magnetic “dipoles” from deep in brain
- 300 sources found inside the head
low spatial resolution
- **ms time resolution**
- **expensive**



30

functional Magnetic Resonance Imaging (fMRI)

- Records concentration of blood oxygen
- 10,000+ cortical cubes ($2 \times 2 \times 2 \text{ mm}^3$)
relatively high spatial resolution
- **Low (0.5-4 seconds) time resolution**
- **expensive**



31

Behavior

Typical arrangement:

- Provide stimulus on each trial
- Record response

Data for analysis:

- Button press, eye movement, body movement
- Reaction time
- Accuracy

32