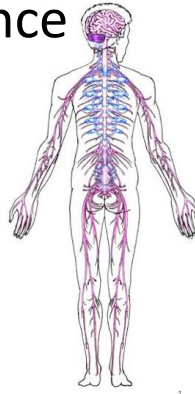


CISC 3250

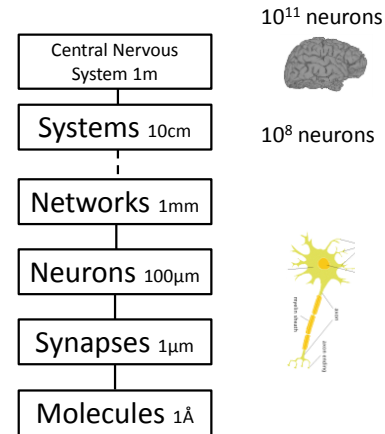
Systems Neuroscience

Neural systems and
neuroanatomy

Professor Daniel Leeds
dleeds@fordham.edu
JMH 332



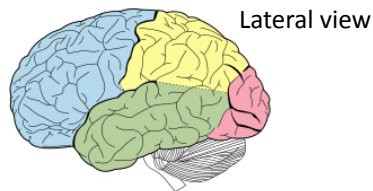
Levels of organization



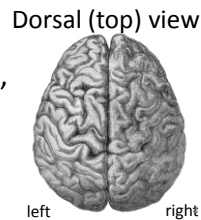
Cerebral cortex broad divisions

- Four lobes

- Frontal ■
- Parietal ■
- Temporal ■
- Occipital ■

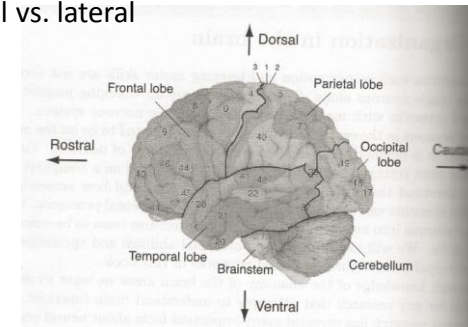


- Two hemispheres: left and right, linked by corpus callosum



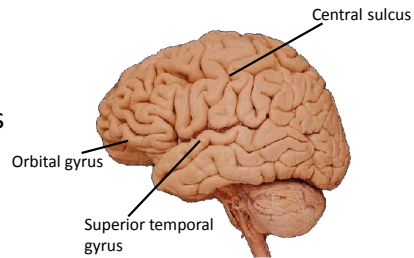
Navigating the cerebral cortex

- Dorsal/superior (top) vs. ventral/inferior (bottom)
- Anterior/rostral (front) vs. posterior/caudal (back)
- Medial vs. lateral



Dividing the cerebral cortex surface

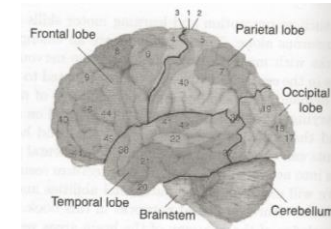
- Sulci – folds
- Gyri – bulges



6

Functional divisions

- Frontal
 - Future planning, personality, judgment, social behavior
 - Motor cortex
- Temporal
 - Auditory cortex
 - High-level vision
- Parietal
 - Spatial vision
 - Primary sensory cortex
 - Visual-auditory-spatial sensory integration
- Occipital
 - Primary visual cortex

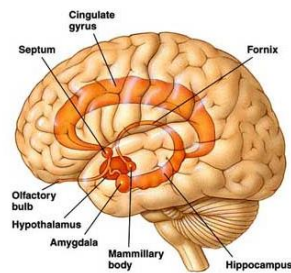


7

Limbic system – memory/emotion

Medial area of cerebral cortex

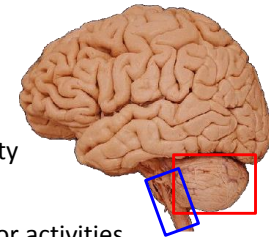
- Hippocampus: memory
- Amygdala: emotion
- Cingulate and parahippocampal gyri



8

The brain beyond the neocortex

- Brain Stem
 - Conduit for spinal cord and cranial nerves
 - Respiratory and cardiac activity
- Cerebellum
 - Plan, coordinate, modify motor activities

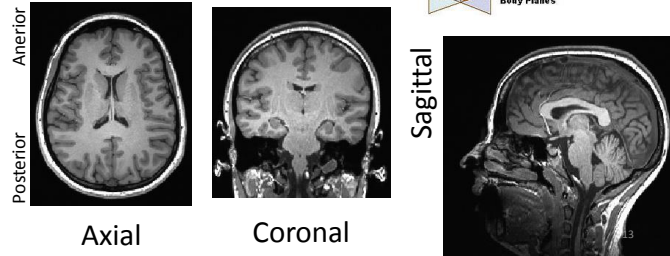
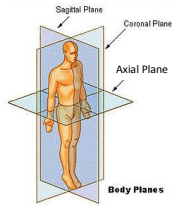


Creative Commons, some right reserved
http://en.wikipedia.org/wiki/File:1806_The_Hypothalamus-Pituitary_Complex.jpg

12

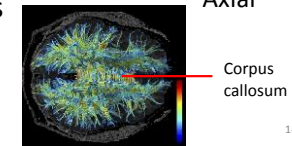
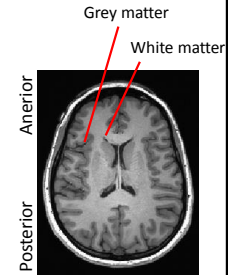
Two dimensional slices of the brain

- Axial (parallel with ground)
- Coronal (halo)
- Sagittal (in profile)



Grey and white matter

- Grey matter – soma, performs “computations”
- White matter (60% of brain) – axons, transmits information
- Tractography finds links between brain regions



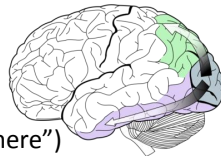
Creative Commons, some rights reserved
<http://en.wikipedia.org/wiki/File:3DSlicer-KubickiPR2007-fig6.jpg>

14

Cortical processing networks

Perception “hierarchy”

- *Primary sensory areas* capture basic sensory properties, or “features”
- More complex representations in higher sensory areas
- Example: Vision
 - Primary visual cortex in occipital pole
 - Anterior flow of information in ventral (“what”) and dorsal (“where”) pathways



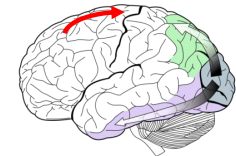
Creative Commons, some rights reserved
http://en.wikipedia.org/wiki/File:Ventral-dorsal_streams.svg

17

Cortical processing networks

Action

- Motor planning and performance is achieved in stages within the frontal lobe
- Motor correction is supervised by the cerebellum

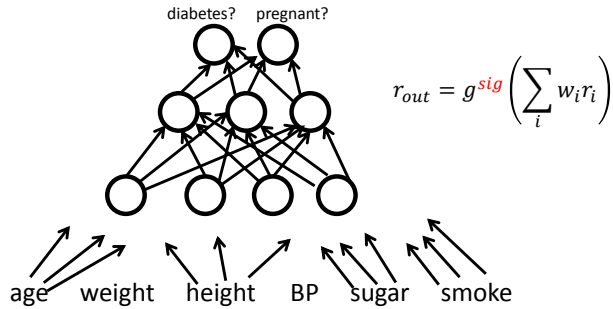


Creative Commons, some rights reserved
http://en.wikipedia.org/wiki/File:Ventral-dorsal_streams.svg

18

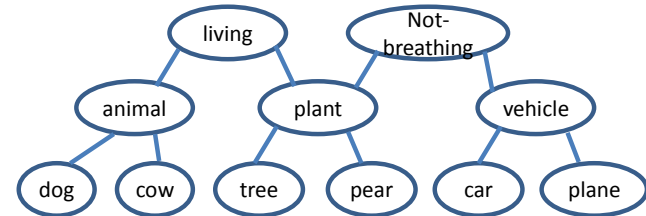
“Deep” learning

Multiple layers of computation in artificial intelligence



19

Deep factor graphs

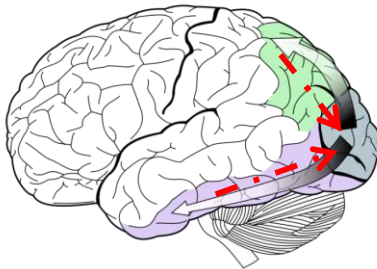


- Hierarchies in reasoning
- WordNet and ImageNet

20

Complexity of cortical networks

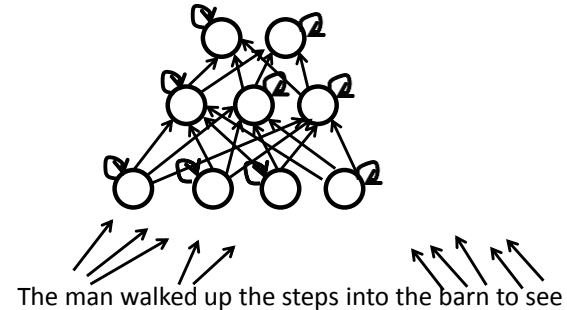
- *Feedback*: connections in both directions along cortical “pathways”



Creative Commons, some rights reserved
http://en.wikipedia.org/wiki/File:Ventral-dorsal_streams.svg

21

Recurrent neural networks

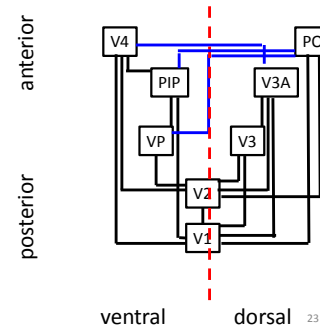


- E.g., Word2Vec: “barn” -> [3, 0, 1, 2, 0, 0, -2]
- Information represented as “neuron” outputs

22

Complexity of cortical networks

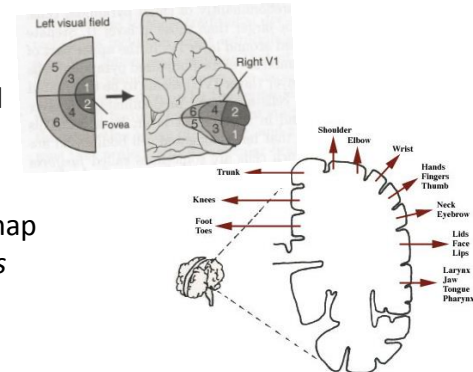
- *Lateral connections:* collaboration among cortical regions at similar stage of processing
- *Multi-level connections:* shortcuts between “early” and “late” processing stages



23

Cortical modules

Groups/“columns” of neurons encoding same property
Subdivisions within cortical region

Walter Crane, <http://www.csuchico.edu/~qmcaffrey/syllabi/CMSDN20120362unit4.html>

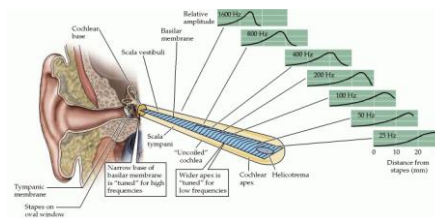
- Retinotopy
- Body part map
Homunculus

Cortical modules

Groups/“columns” of neurons encoding same property

Subdivisions within cortical region

- Retinotopy
- Body part map
Homunculus
- Tonotopy

<http://www.ncbi.nlm.nih.gov/books/NBK10946/>


26

Recording activity in the brain

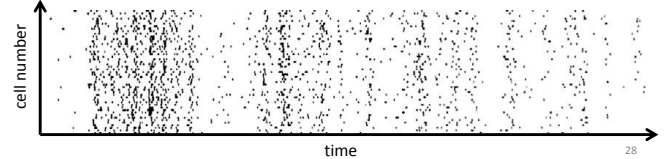
- Electrode recordings
 - Invasive
 - Single neurons close together
- Neuroimaging
 - Non-invasive
 - Hundreds-millions of neurons broadly distributed
- Behavior
 - Non-invasive
 - Overall cognition

27

Electrode recordings



- Membrane potentials
- Spike times
- High temporal resolution (ms)
- High spatial resolution (individual neurons)
- Low field of view (small recording area)

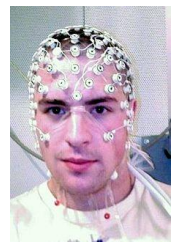


cell number


time

28

Electroencephalography (EEG)




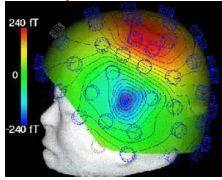
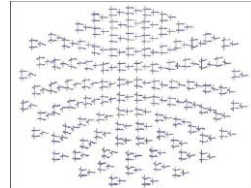
- Records electric fields at skull surface
- ~100 sensors across the head
- low spatial resolution
- high (ms) time resolution
- cheap



29

Magnetoencephalography (MEG)

- Records magnetic “dipoles” from deep in brain
- 300 sources found inside the head
- low spatial resolution
- ms time resolution
- expensive

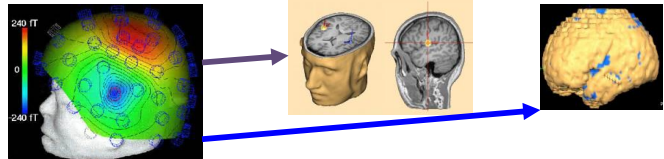
30

This slide uploaded late, not on exam 1

Source localization – EEG and MEG

From recordings at surface:

- extrapolate limited localized “dipoles” of activity within the brain
- extrapolate broad regions of activity



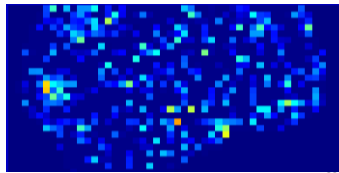
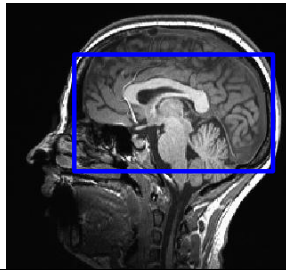
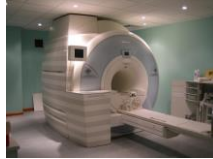<https://www.cogsci.mq.edu.au/facilities/erp/documents/presentations/an%20introduction%20to%20spatial%20analyses.pdf>

31

functional Magnetic Resonance Imaging (fMRI)



- Records concentration of blood oxygen
- 10,000+ cortical cubes ($2 \times 2 \times 2 \text{ mm}^3$)
relatively high spatial resolution
- Low (0.5-4 seconds) time resolution
- expensive



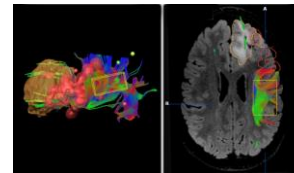
32

This slide uploaded late, not on exam 1 Tractography: Diffusion Tensor Imaging (DTI)

Uses MRI

Track flow of water along axon tracts

- Pick source location, see where water flows to



Each color is a different white matter pathway

https://www.mayfieldclinic.com/PE-fMRI_DTI.HTM

34